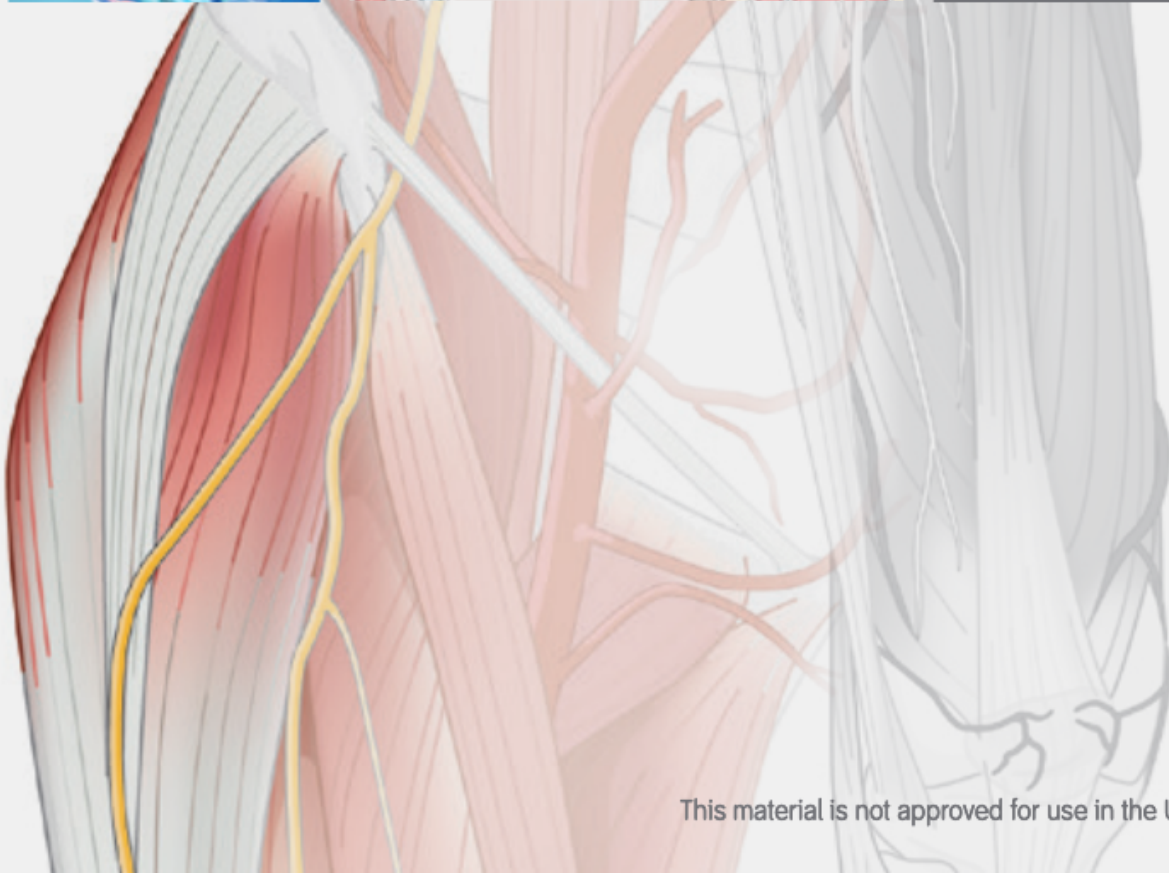
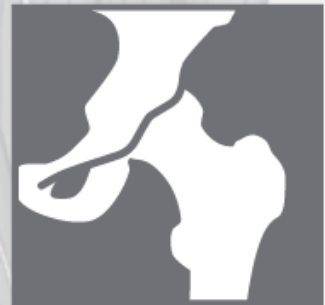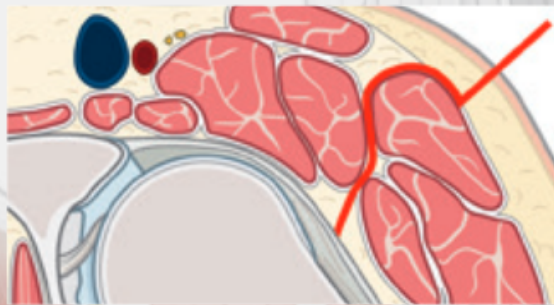

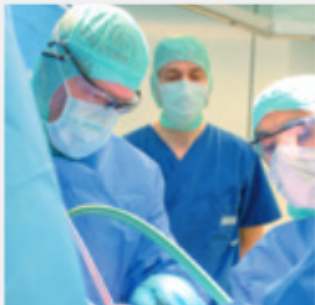
Pocket guide

Minimally invasive hip endoprosthesis

Direct Anterior Approach for Total Hip Replacement
Michael Leunig, Switzerland

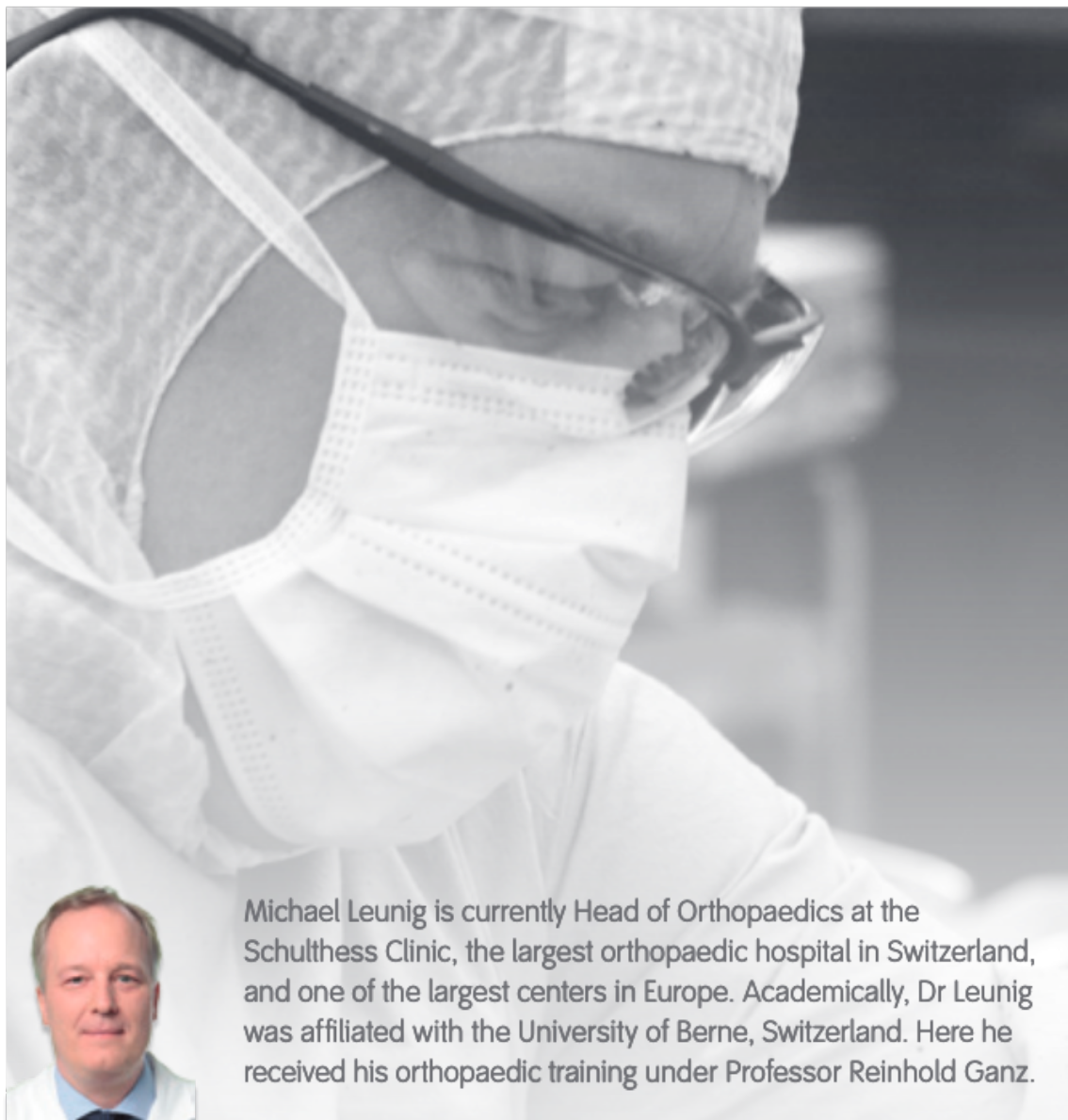

Disclaimer Great care has been taken to maintain the accuracy of the information contained in the publication. However, neither KLEOS, nor the authors can be held responsible for errors or any consequences arising from the use of the information contained in this publication. The statements or opinions contained in editorials and articles in this journal are solely those of the authors thereof and not of KLEOS. The products, procedures, and therapies described are only to be applied by certified and trained medical professionals in environments specially designed for such procedures. No suggested test or procedure should be carried out unless, in the reader's professional judgment, its risk is justified. Because of rapid advances in the medical sciences, we recommend that independent verification of diagnosis, drugs dosages, and operating methods should be made before any action is taken. Although all advertising material is expected to conform to ethical (medical) standards, inclusion in this publication does not constitute a guarantee or endorsement of the quality or value of such product or of the claims made of it by its manufacturer. Some of the products, names, instruments, treatments, logos, designs, etc. referred to in this journal are also protected

by patents and trademarks or by other intellectual property protection laws even though specific reference to this fact is not always made in the text. Therefore, the appearance of a name, instrument, etc. without designation as proprietary is not to be construed as a representation by the publisher that it is in the public domain. This publication, including all parts thereof, is legally protected by copyright. Any use, exploitation or commercialization outside the narrow limits of copyrights legislation, without the publisher's consent, is illegal and liable to prosecution. This applies in particular to photostat reproduction, copying, scanning or duplication of any kind, translating, preparation of microfilms and electronic data processing and storage. Institutions' subscriptions allow to reproduce tables of content or prepare lists of articles including abstracts for internal circulation within the institutions concerned. Permission of the publisher is required for resale or distribution outside the institutions. Permission of the publisher is required for all other derivative works, including compilations and translations. Permission of the publisher is required to store or use electronically any material contained in this journal, including any article or part of an article. For inquiries contact the publisher at the address indicated.

Table of contents

Introduction	5
Instruments	6
Anatomy	8
Description of the approach	9
Patient positioning	10
Defining the skin incision	11
Disinfection and draping	12
Operative procedure	13
Incise the skin	13
Conduct the epifascial approach	14
Identify the anterior superior iliac spine	15
Conduct the subfascial approach	16
Identify the lateral circumflex artery and perform hemostasis	17
Identify the anterior edge of the greater trochanter	18
Expose the capsule and identify the reflected head of the rectus femoris	20
Dislocate the femoral head	22
Perform the femoral neck osteotomy and extract the head	23
Position the patient for preparing the femur and releasing the capsule	24
Mobilize the femur anteriorly	25
Place the patient in an inverse figure-of-four position for femoral exposure	26
Prepare the femur (femur-first technique)	27
Prepare the acetabulum	28
Insert the cup	30
Assess cup orientation and stability	31
Insert the stem	32
Close the wound	33



Michael Leunig is currently Head of Orthopaedics at the Schulthess Clinic, the largest orthopaedic hospital in Switzerland, and one of the largest centers in Europe. Academically, Dr Leunig was affiliated with the University of Berne, Switzerland. Here he received his orthopaedic training under Professor Reinhold Ganz.

Dr Leunig's busy hip practice spans the entire spectrum from joint preservation, to hip replacement and revision surgery. Based on his commitments in 2005, he has been elected a member of the International Hip Society. In addition, he is a member of several international research networks including the Academic Network of Conservational Hip Outcomes Research (ANCHOR) and the Multicenter Arthroscopy of the Hip Outcomes Research Network (MAHORN). He is also a board member of the Müller Foundation North America and the International Society of Orthopaedic Centers (ISOC). Based on his clinical research, Dr Leunig is Associate International Editor of *Clinical Orthopedics and Related Research*.

Dr Leunig performs the direct anterior approach as his standard approach for total hip arthroplasty since 2005, performing over 400 hip surgeries annually.

Introduction

Minimally invasive total hip arthroplasty (THA) has gained in popularity in recent years. One of the approaches commonly used for this is the direct anterior approach (DAA). Advantages of the DAA include:

- Sparing of muscles (1,2)
- Improved joint stability and low dislocation rate (3)
- Rapid postoperative recovery and a simple rehabilitation regimen (4)
- Easy bilateral hip replacement [5]

Due to these advantages, the indications for THA can be expanded. For example, patients with neuropathic disease (where dislocation rate is higher), can be operated on as the dislocation risk is reduced.

Outlined in this 'Pocket guide' are the key steps and refresher information for performing the DAA. A clinical video 'Minimally Invasive Anterior Approach for Total Hip Replacement using POLARSTEM[®]* and R3[°] Cup' is also available online and as a DVD.

References

1. **Bergin PF, Doppelt JD, Kephart CJ, et al** (2011) Comparison of minimally invasive direct anterior versus posterior total hip arthroplasty based on inflammation and muscle damage markers. *J Bone Joint Surg Am* 93(15):1392-8.
2. **Bremer AK, Kalberer F, Pfirrmann CW, et al** (2011) Soft-tissue changes in hip abductor muscles and tendons after total hip replacement: comparison between the direct anterior and the transgluteal approaches. *J Bone Joint Surg Br* 93(7): 886-9.
3. **Masonis J, Thompson C, Odum S** (2008) Safe and accurate: learning the direct anterior total hip arthroplasty. *Orthopedics* 31(12 Suppl 2).
4. **Mayr E, Nogler M, Benedetti MG, et al** (2009) A prospective randomized assessment of earlier functional recovery in THA patients treated by minimally invasive direct anterior approach: a gait analysis study. *Clin Biomech* (Bristol, Avon) 24(10):812-8.
5. **Aghayev E, Beck A, Staub LP, et al** (2010) Simultaneous bilateral hip replacement reveals superior outcome and fewer complications than two-stage procedures: a prospective study including 1819 patients and 5801 follow-ups from a total joint replacement registry. *BMC Musculoskelet Disord* 11:245

* POLARSTEM has not been cleared or approved for commercial distribution by the US Food and Drug Administration

Instruments

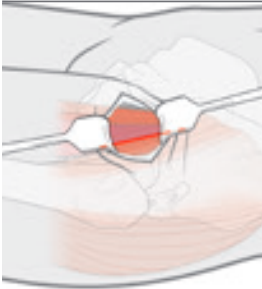
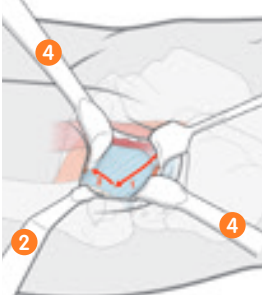
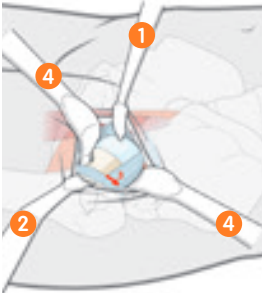

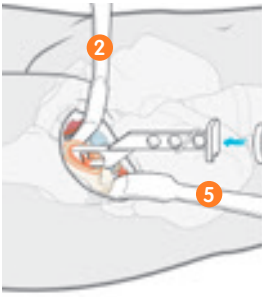
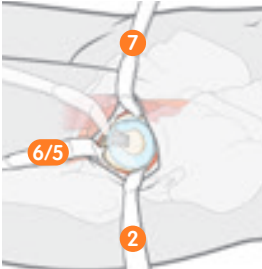
For a direct anterior approach to hip arthroplasty, in addition to standard surgical instruments found in every operating room, use a set of soft-tissue-sparing instruments. The retractors' supporting surface is enlarged to better distribute the stress and the edges are curved to prevent them from cutting into tissue. You will find these instruments, dedicated to the direct anterior approach, highlighted within this pocket guide.

Retractors for anterior approach

Set.-no 75210259



Retractors for anterior approach

	Subfascial approach	Short blunt retractors <i>(non-approach specific instruments)</i>
	Capsular exposure	2 S Bone lever expanded double curved <i>Art. No. 24.51.57 SAP No. 775023836</i> 4 S Hip lever, blunt w. long soft-tissue protection <i>Art. No. 24.51.40L SAP No. 75100667</i>
	Capsular exposure (cont)	1 S Bone Lever w. long soft-tissue protection <i>Art. No. 24.5137.L SAP No. 75100665</i> 2 S Bone lever expanded double curved <i>Art. No. 24.51.57 SAP No. 775023836</i> 4 S Hip lever, blunt w. long soft-tissue protection <i>Art. No. 24.51.40L SAP No. 75100667</i>
	Anterior mobilization of the femur	Blunt retractors <i>(non-approach specific instruments)</i>
	Femoral preparation	2 S Bone lever expanded double curved <i>Art. No. 24.51.57 SAP No. 775023836</i> 5 S Trochanteric lever <i>Art. No. 24.51.72 SAP No. 75023837</i>
	Acetabular preparation	2 S Bone lever expanded double curved <i>Art. No. 24.51.57 SAP No. 775023836</i> 5 S Trochanteric lever <i>Art. No. 24.51.72 SAP No. 75023837</i> 6 S Hip Lever <i>Art. No. 24.51.90 SAP No. 775100668</i> 7 S Pelvis lever <i>Art. No. 24.51.73 SAP No. 75100669</i>

Anatomy

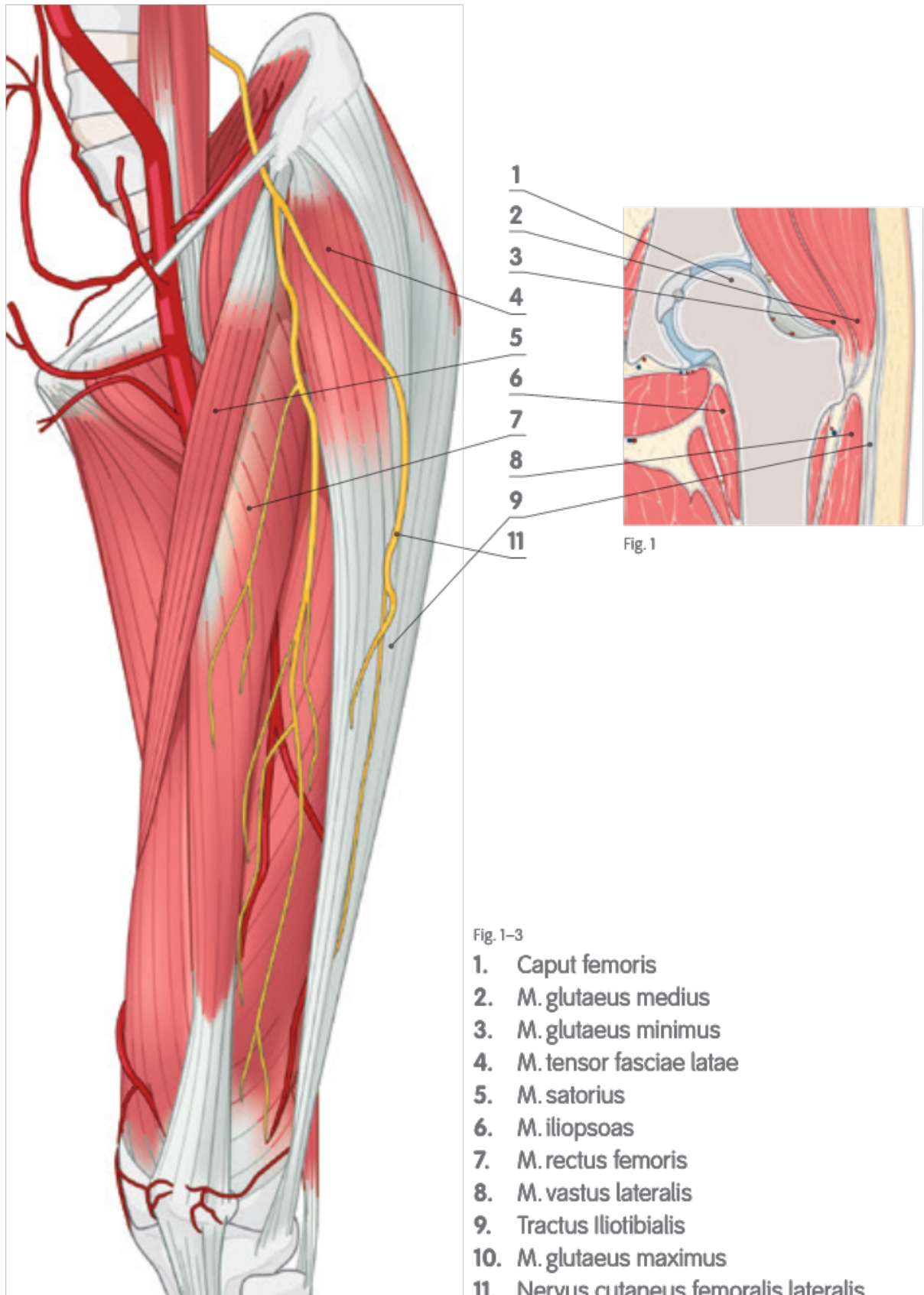


Fig. 2

Description of the approach

The Direct Anterior Approach to hip arthroplasty, can be summarized as follows:

- make an oblique incision in the skin crease
- incise the sheath of the tensor fascia longitudinally and peel it out
- perform blunt dissection, to open up the gap between the tensor fascia sheath and the tensor fascia muscle, to locate the femoral neck.

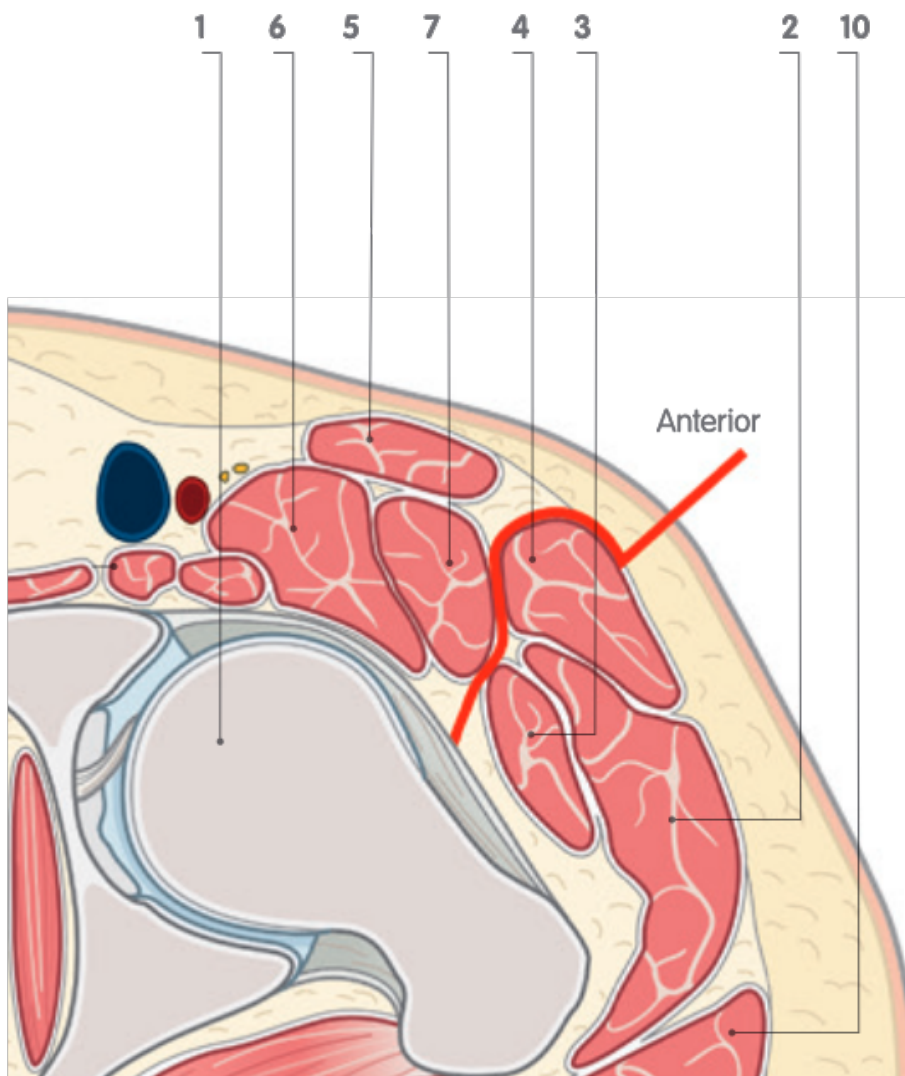


Fig. 3

Patient positioning

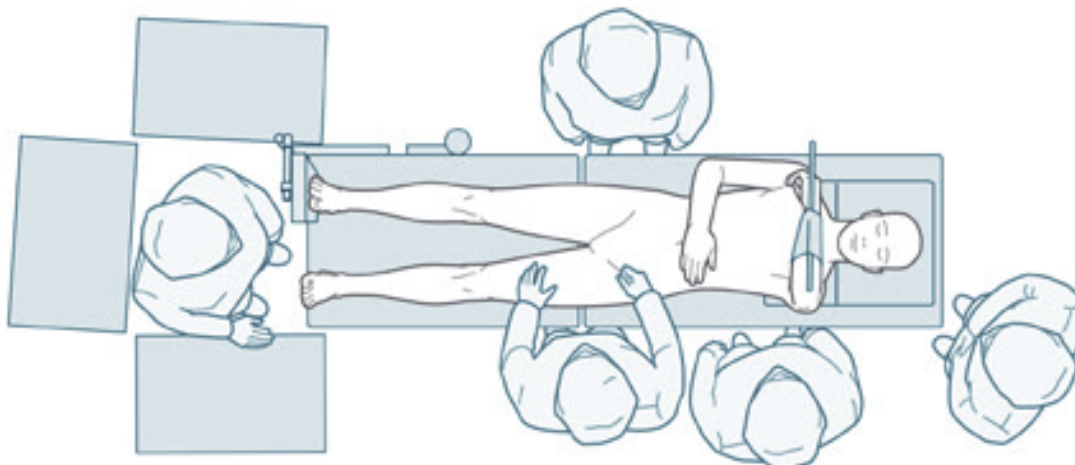


Fig. 4

It is important to correctly position the patient on the operating table. The table must have the option of lowering both legs, with the break in the table directly under the hip joint.

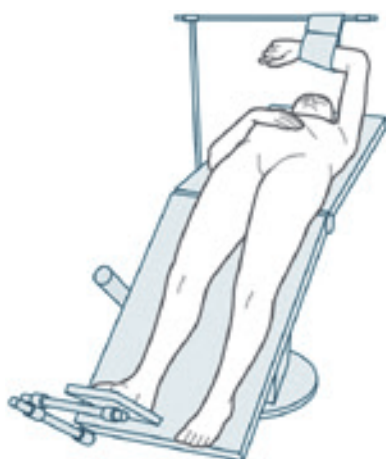

Fig. 5

A foot plate on the non-operated side prevents the patient from sliding off the table. Additionally, a side post, located on the non-operated side, can be used to position the operated leg in a figure-of-four position during surgery. The surgeon stands to the left of his assistant, while the second assistant stands on the opposite side of the table.

Defining the skin incision

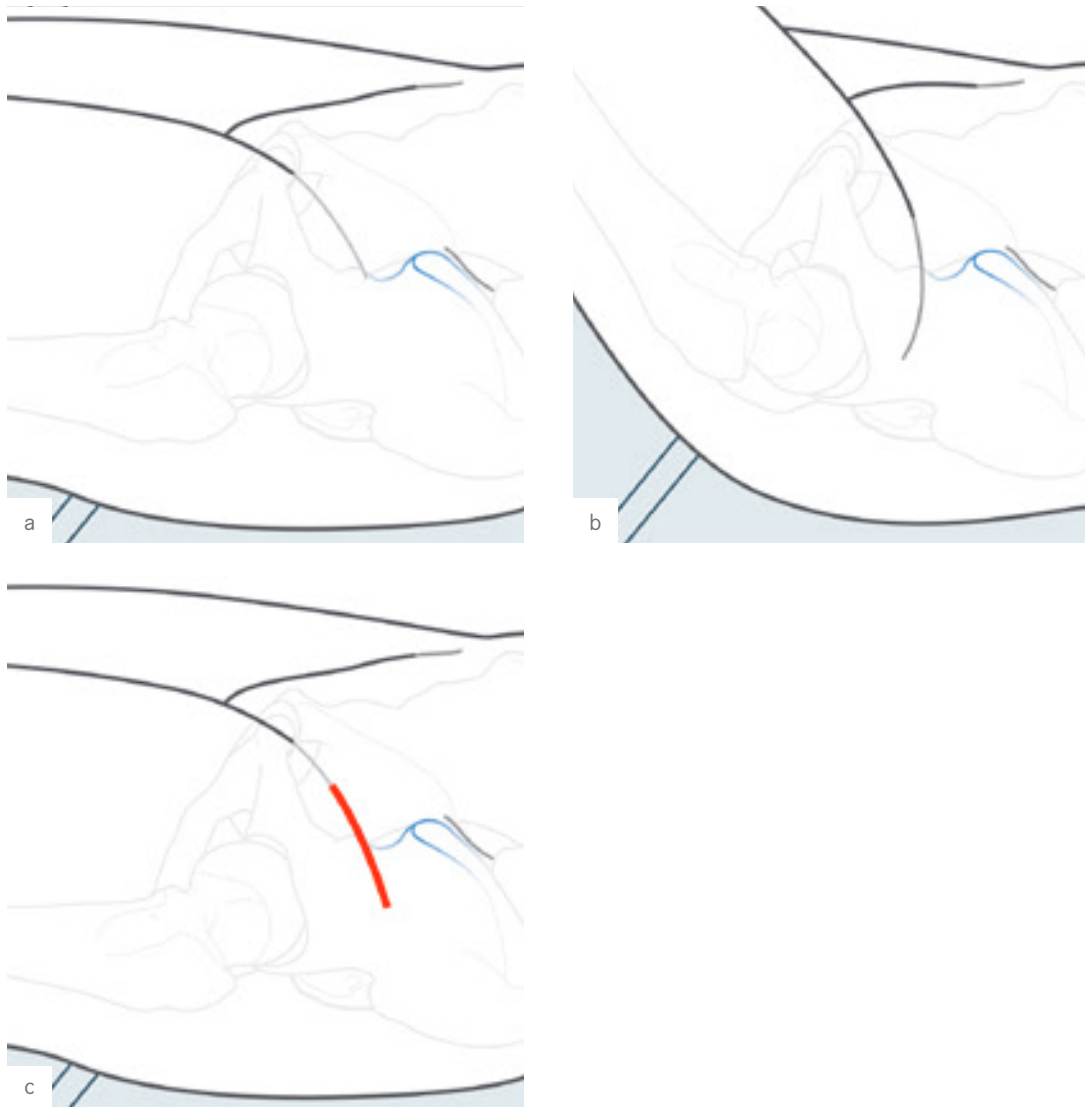


Fig. 6

When defining the incision, it is important to locate the landmarks of the anterior superior iliac spine (ASIS).

The traditional approach is longitudinal, two centimeters distal and lateral to the ASIS. However, in this approach, use an oblique incision in the skin crease, which is identified during flexion of the hip. (Figures 6a-c)

The classic longitudinal incision is perpendicular to the tension (Langer's) lines. This can result in a wide scar and wound healing problems. The oblique (bikini-type) incision, however, is in the same direction as the tension lines. This means there is reduced wound stress, which can lead to better wound healing and a less pronounced scar.

Disinfection and draping

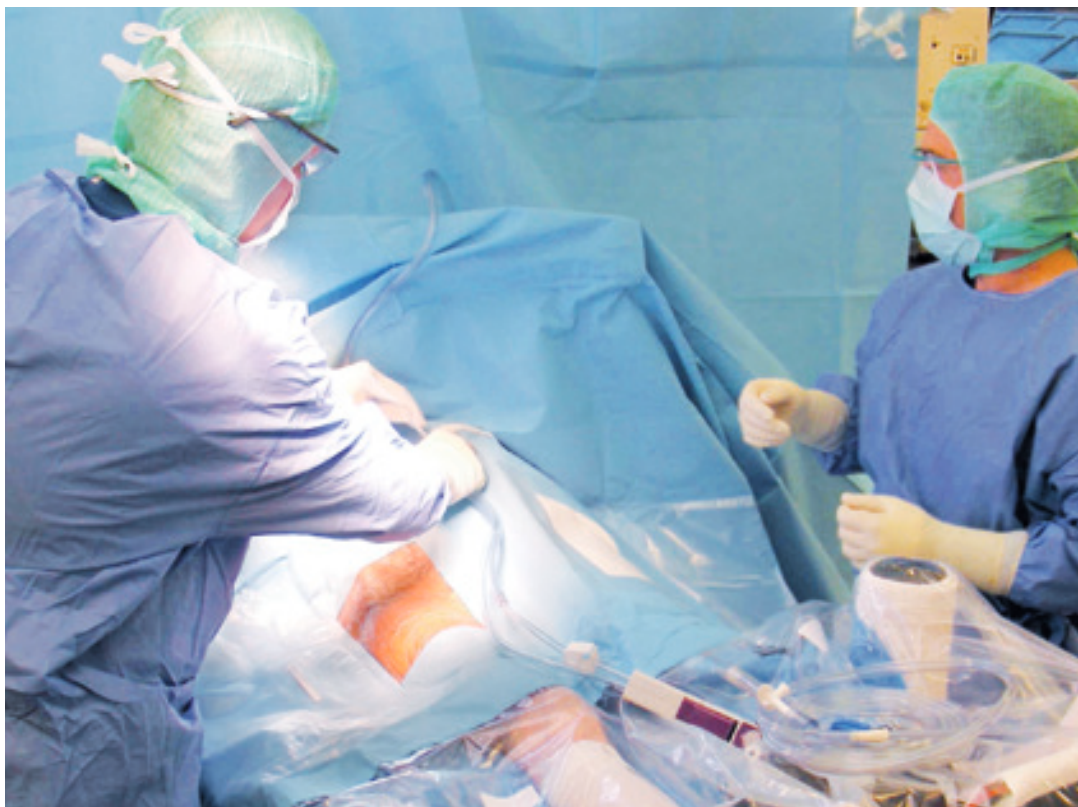

Fig. 7

Now mark the ASIS and the skin incision. You can either drape both legs or the side of the arthritic hip only. Draping both legs is particularly helpful for beginners of the direct anterior approach, as it permits a much better range of motion for both extremities during surgery and makes it easier to operate on difficult hips. With more experience with the procedure, just the hip(s) can be draped, which can reduce time in surgery.

Draping of both legs:

- 1) Hold each hip in slight flexion and abduction with extended knees. Adduct the arthritic hip to also disinfect the buttock and put a sterile paper towel underneath. Between both legs, place a sterile diaper.
- 2) Finish disinfection including both feet and put sterile stockings on.
- 3) Use first a U- and then a W-paper towel and close the field with a sterile curtain.
- 4) Transparent adhesive tapes protect the skin during surgery.

Draping the hip only:

This method is similar to a horizontal drape used for hip fractures.

- 1) Disinfect the hip from the first rib to the abdominal middle line down to the mid-thigh.
- 2) Cover the area with a transparent tape, followed by the horizontal drape (3M).

Operative procedure

Incise the skin

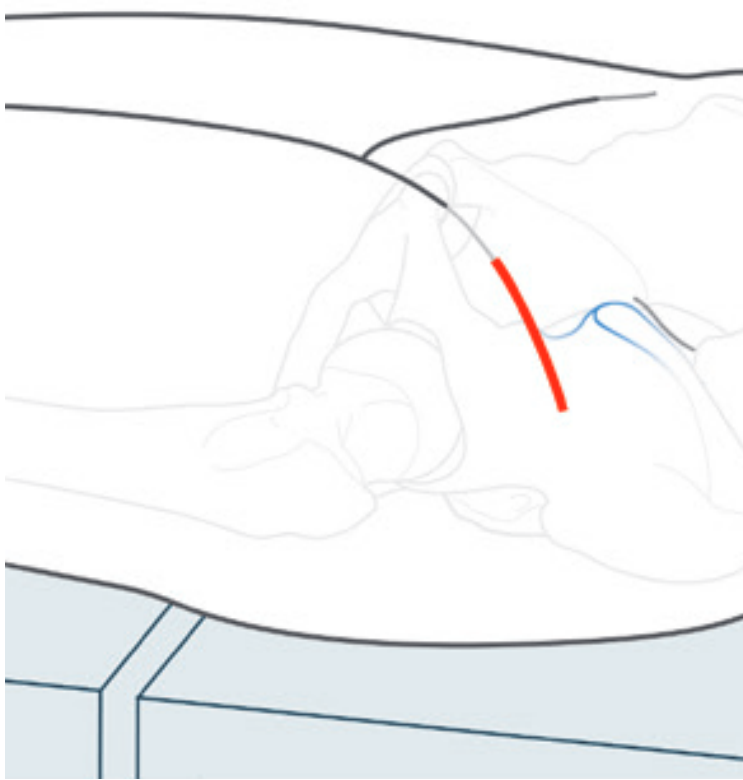


Fig. 8

Before incising the skin, identify the ASIS once more and follow your previously-drawn marking.

The skin is incised obliquely. The first incision involves cutting through the dermal layer, followed by hemostasis. Avoid going too far medially when incising.

Conduct the epifascial approach

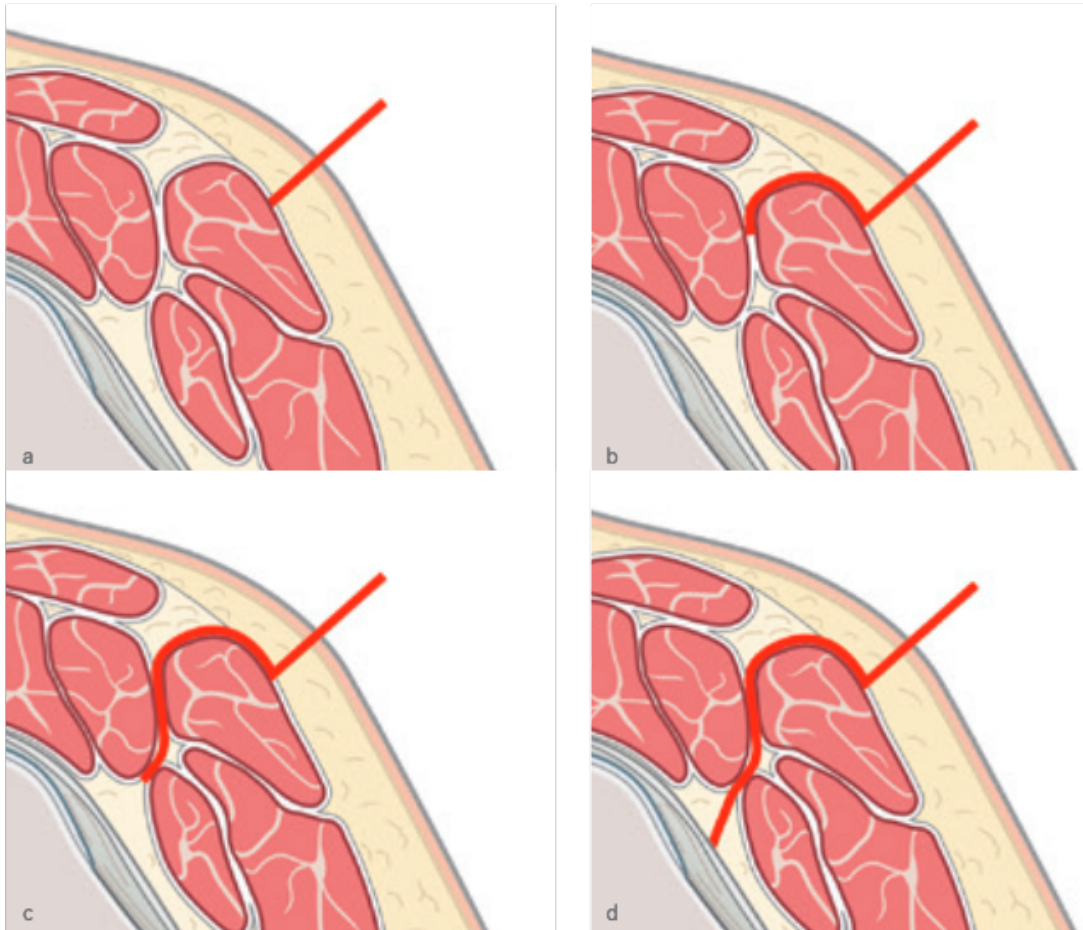


Fig. 9

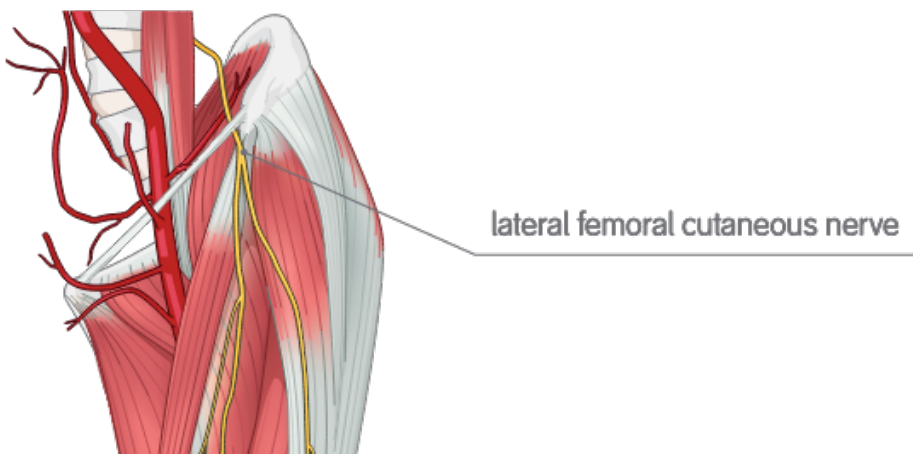


Fig. 10

Thereafter, proceed with the incision in a longitudinal direction to avoid the course of the lateral femoral cutaneous nerve.

The transverse view of the femur shows where you have to go through the fascia layer.

Identify the anterior superior iliac spine

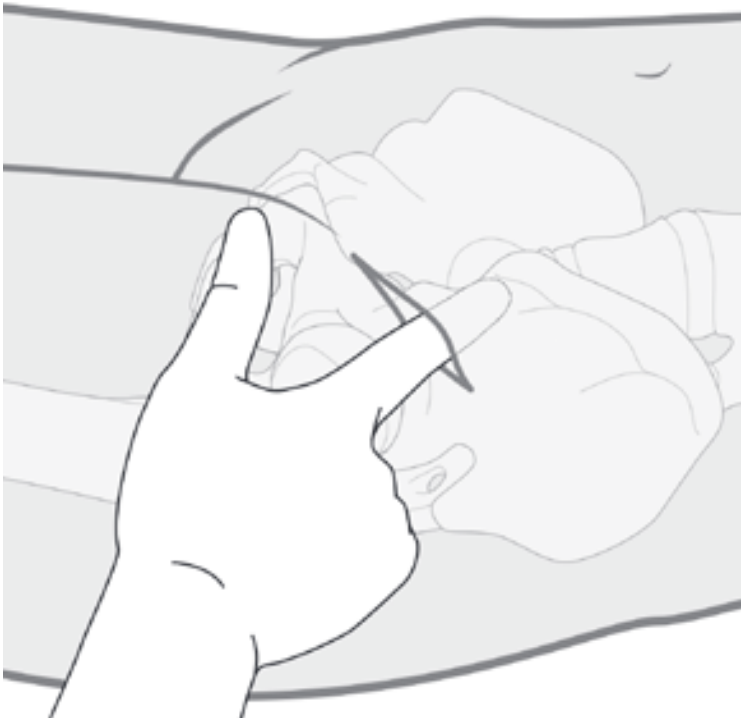


Fig. 11

Identify the anterior superior iliac spine to ensure that you are above the sheath of the tensor fascia. The bluish appearance of this fascial layer indicates your incision site. Use a securing suture to prevent the incision extending medially.

Conduct the subfascial approach

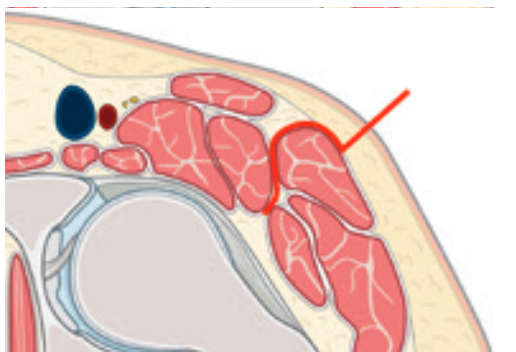


Fig. 12

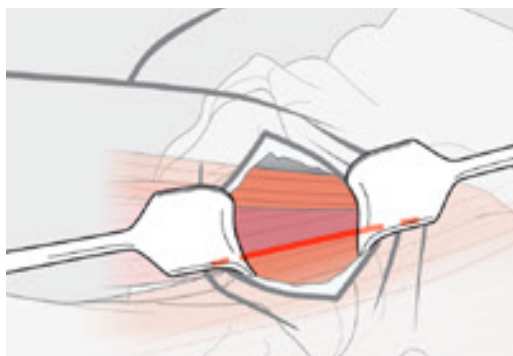


Fig. 13

As previously mentioned, proceed with the incision in a longitudinal direction, rather than the oblique direction.

Incise the sheath of the tensor fascia longitudinally and peel it out. It is helpful to put a towel roll under the knee to release the tension on the rectus femoris and tensor fasciae latae (TFL) muscles.

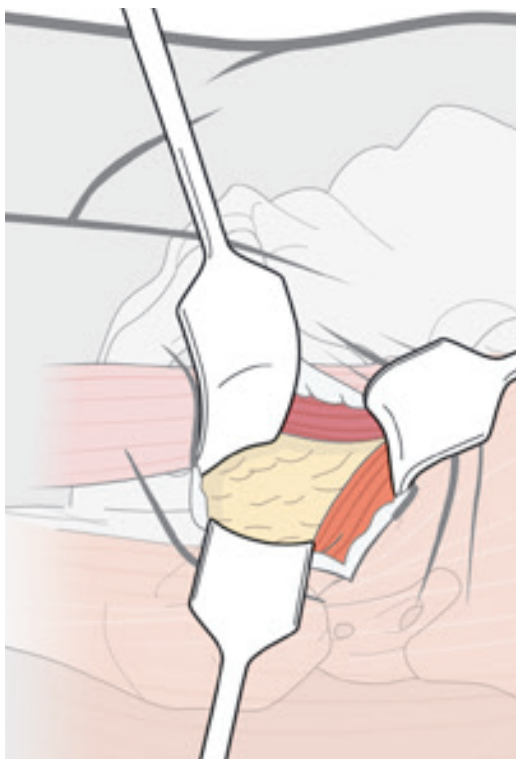


Fig. 14

Insert your finger and perform blunt dissection, opening up the gap between the tensor fascia sheath and the tensor fascia muscle. The three short blunt retractors are then used to open up a window, enabling you to go deeper with your dissection.

Identify the lateral circumflex artery and perform hemostasis

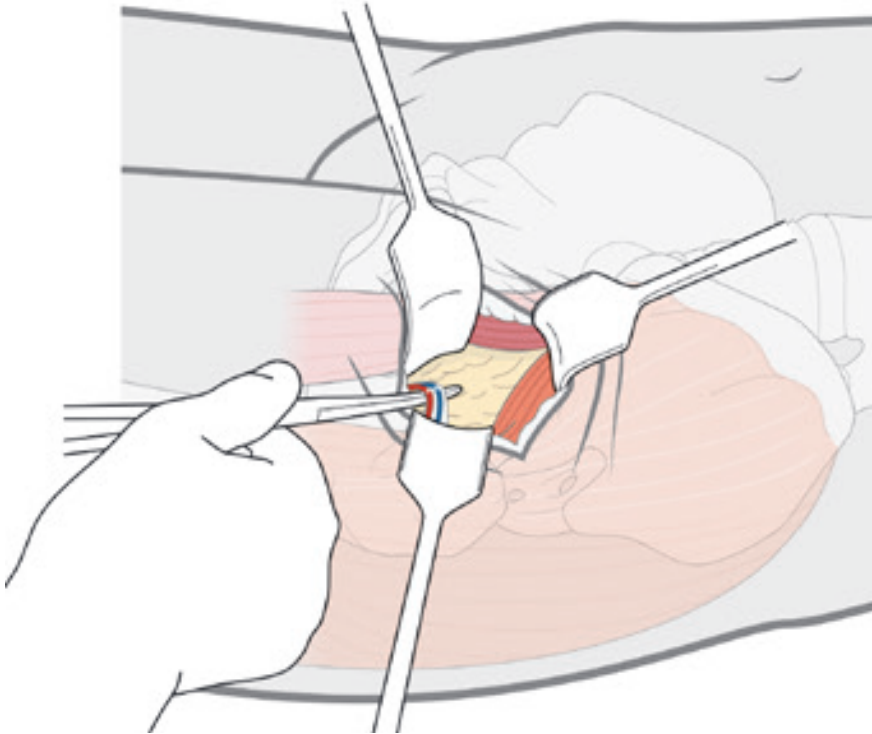


Fig. 15

Identify the vascular branch of the lateral circumflex artery, which is located at the inferior margin of your incision. You can either coagulate this blood vessel in younger patients, or ligate it in older patients with arteriosclerosis. Sometimes it is not even necessary to ligate this vessel. Now descend to the deeper part of the tissue and the capsule.

Identify the anterior edge of the greater trochanter

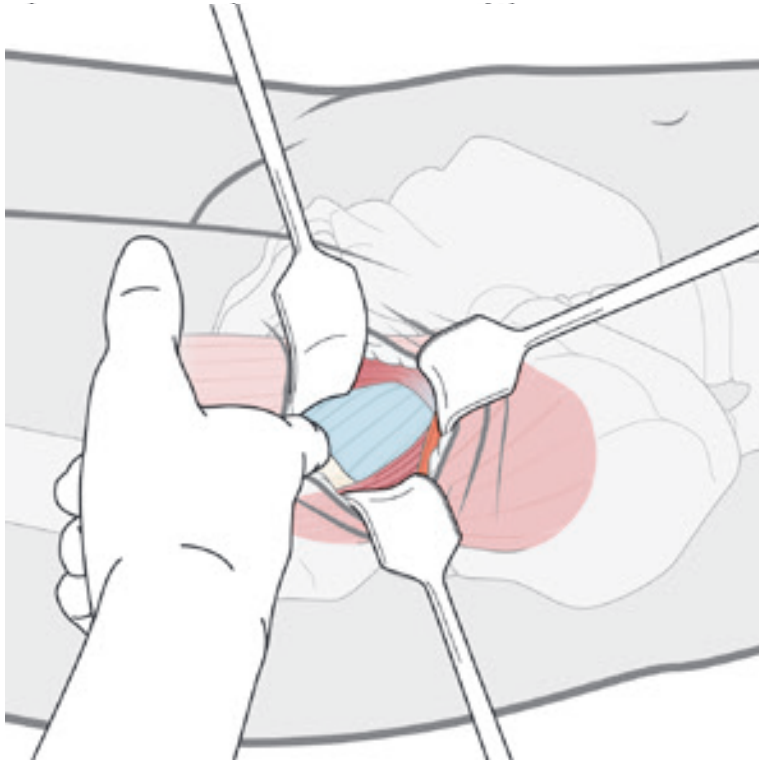


Fig. 16

It is helpful to palpate the anterior edge of the greater trochanter with your finger, as it acts as a landmark to help you locate the femoral neck.

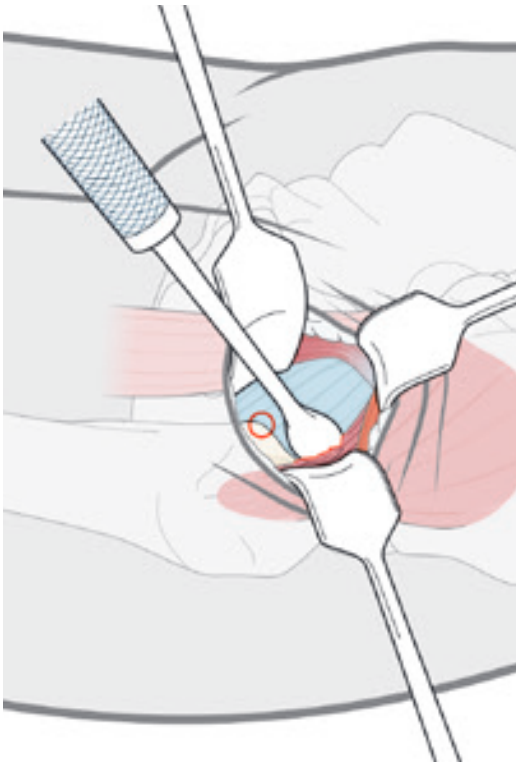


Fig. 17

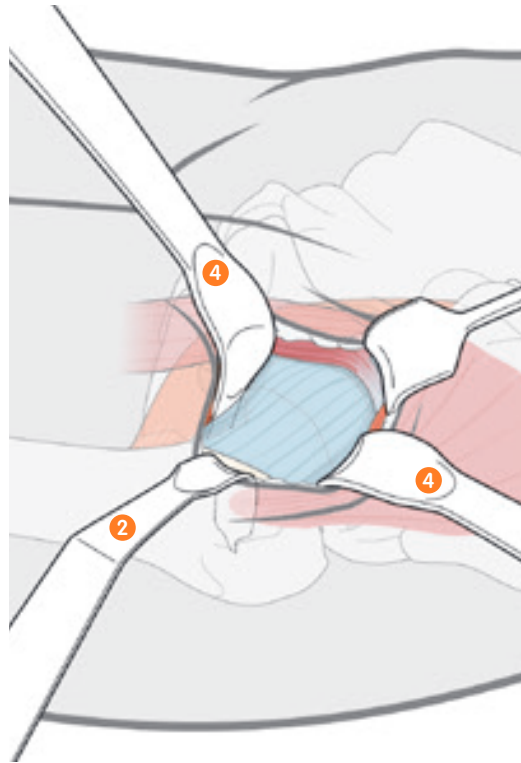


Fig. 18

Once you have located the femoral neck, use a Cobb elevator to lift the gluteus minimus muscle off the capsule. (Figure 17)

Then place curved retractors between the capsule and the gluteus minimus (S Hip lever, blunt w. long soft-tissue protection ④), between the trochanter and the tensor fasciae latae (S Bone lever expanded double curved ②) and, finally, around the medial part of the femoral neck into the obturator foramen (④). These three retractors allow good exposure of the joint. (Figure 18)

Expose the capsule and identify the reflected head of the rectus femoris

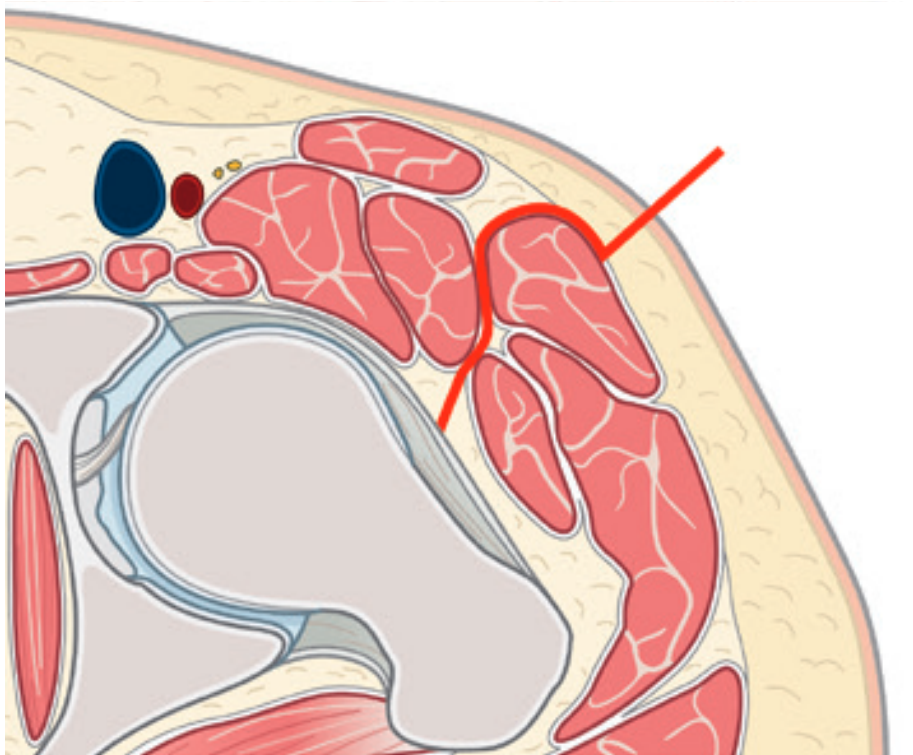


Fig. 19

Now you have reached the capsule. After removing the fatty tissue, you have a good view of the top of the capsule and you need to identify the indirect head of the rectus femoris. Here you see the rectus femoris muscle.

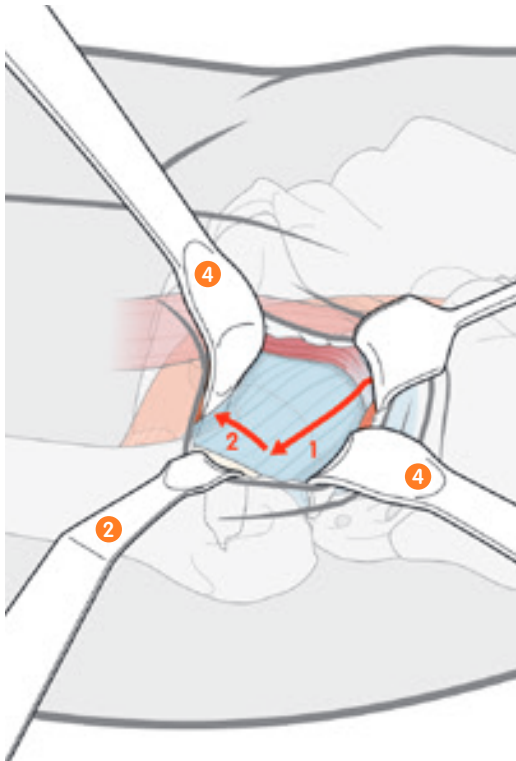


Fig. 20

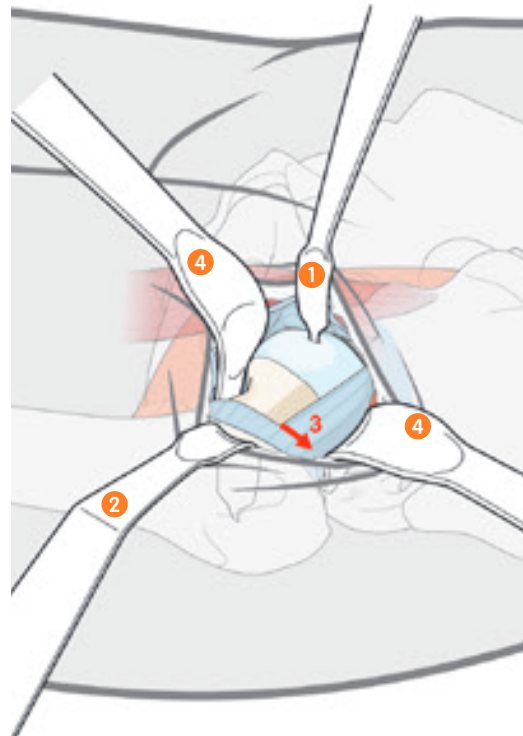


Fig. 21

The incision follows the rectus femoris muscle down to the anterior edge of the greater trochanter (1) - the first step of the capsulotomy. In the second step, the incision then curves towards the medial aspect of the femoral neck (2). (Figure 20)

After the capsule is opened (3), the retractors are placed intracapsularly. Place one retractor on top of the femoral head (S Bone lever w. long soft-tissue protection ①), the next around the medial aspect of the femoral neck (S Hip lever, blunt w. long soft-tissue protection ④), and the final retractor around the lateral aspect of the femoral head (④). (Figure 21)

Dislocate the femoral head

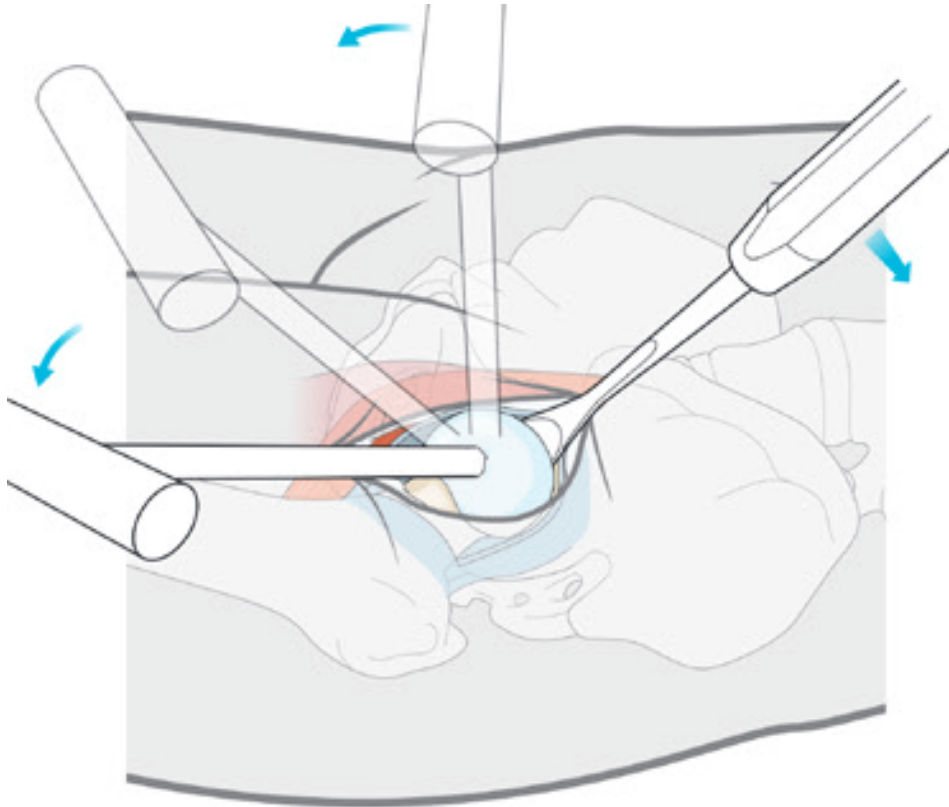


Fig. 22

A corkscrew is then inserted into the femoral head. Optionally, it can be helpful to dislocate the femoral head before performing the neck cut. To do this, insert a spoon into the gap between the femoral head and the socket. With the combined rotation of both instruments, the femoral head can be subluxated out of the joint to tear the round ligament.

Perform the femoral neck osteotomy and extract the head

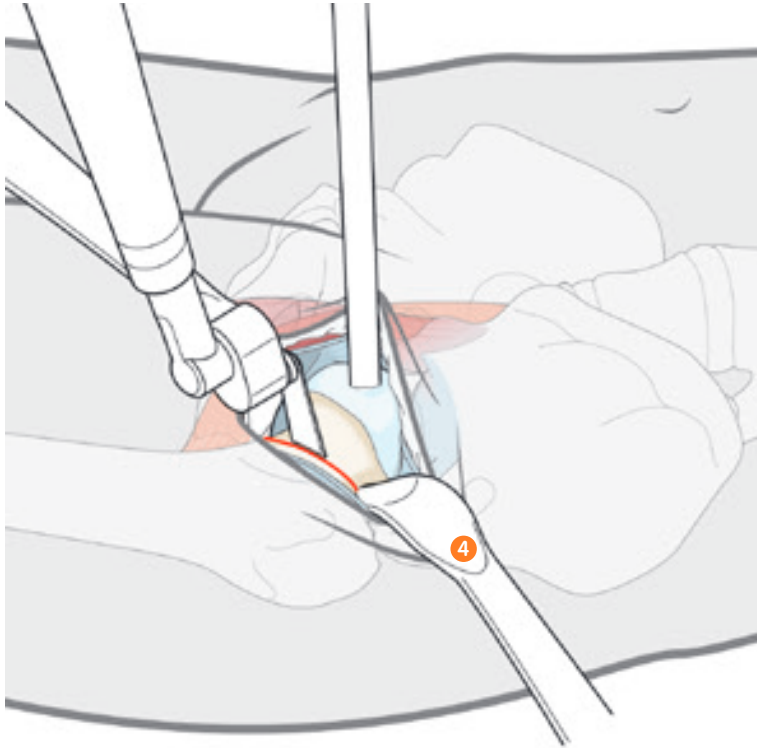


Fig. 23

Using a long plate on the oscillating saw, perform the neck osteotomy and extract the femoral head.

The S Hip lever (4) is used as a landmark to perform the cut and to ensure the correct angle is obtained. The saw cut should end at the inferior end of this retractor, and should not go distal to this.

Position the patient for preparing the femur and releasing the capsule

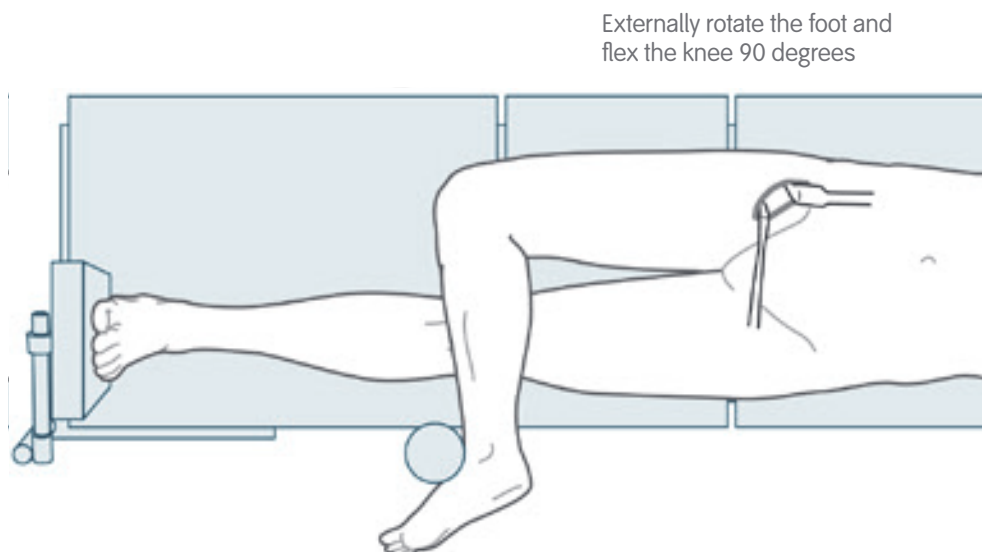


Fig. 24

Use the figure-of-four position for femoral preparation and release. This requires the operated leg to be placed on top of the other leg, with the knee bent 90 degrees.

With the hip in this external rotation, the first step is to identify the calcar area. Proceed laterally, to the capsule and the gluteus minimus. It is very important to dissect out the strong adhesions between the capsule and the gluteus minimus without damaging the latter.

Mobilize the femur anteriorly

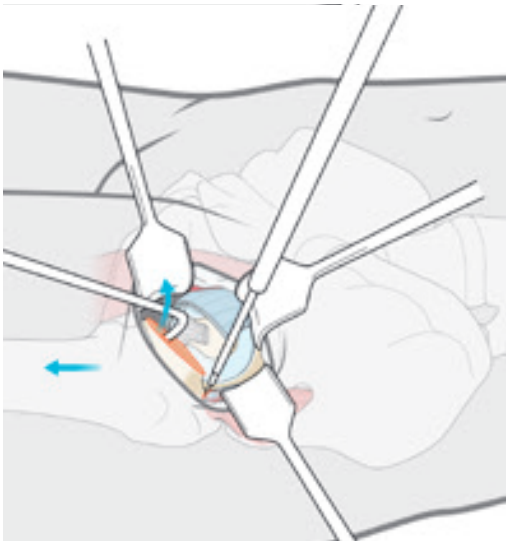


Fig. 25

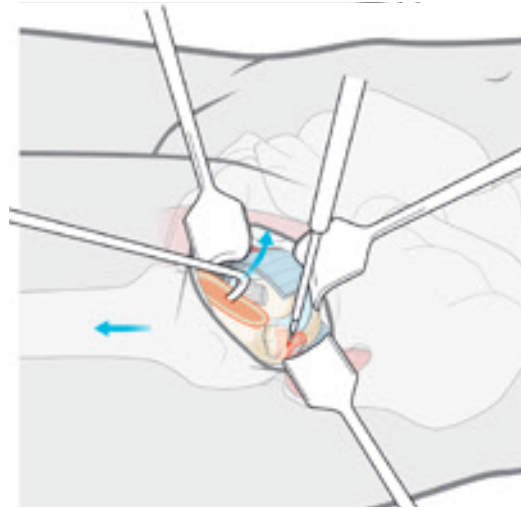


Fig. 26

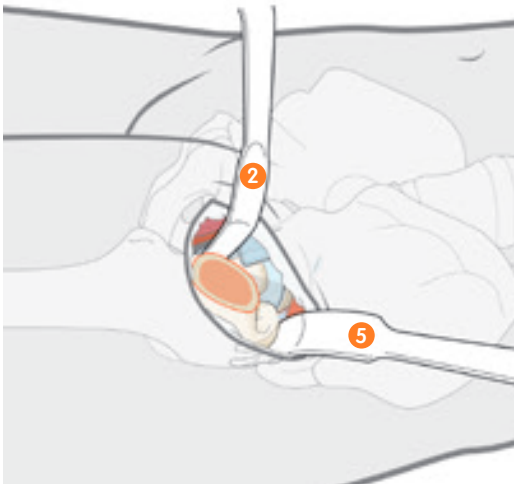


Fig. 27

The most crucial part of the direct anterior approach is mobilization of the femur.

It is very important to be able to mobilize the femur anteriorly (Figure 25). With the nurse pulling on the leg, separate the capsule from the gluteus minimus. Incise the capsule within the trochanter with your electric knife, pulling the femur anteriorly (Figure 26). Place one retractor behind the greater trochanter (S Trochanteric lever **5**), and one around the medial part of the femur (S Bone lever expanded double curved **2**) (Figure 27)

Place the patient in the inverse figure-of-four position for femoral exposure

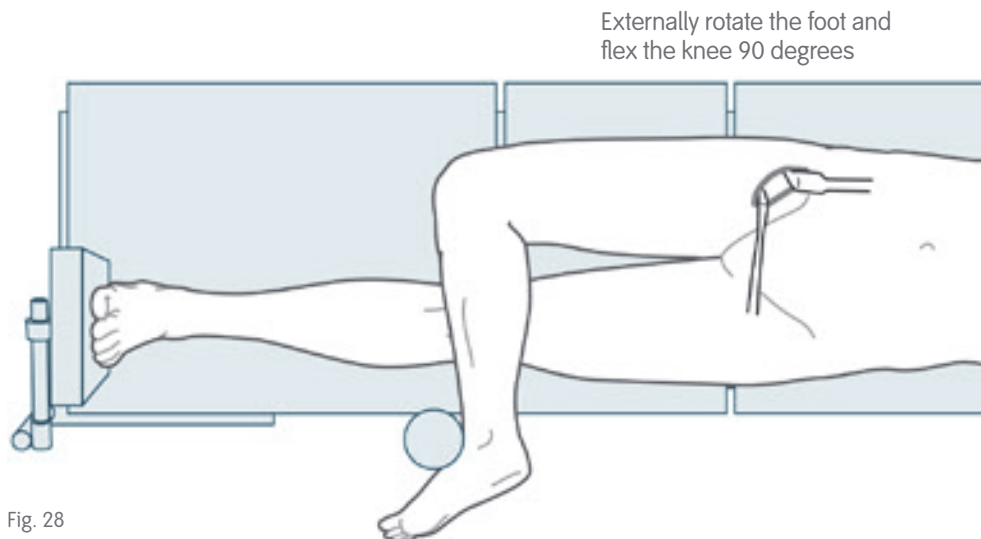


Fig. 28

After releasing the femur, use the so-called inverse figure-of-four position to expose the femur. Find the two retractors placed around the proximal femur. Sometimes the figure-of-four (not inverse figure-of-four) position is sufficient to expose the femur.

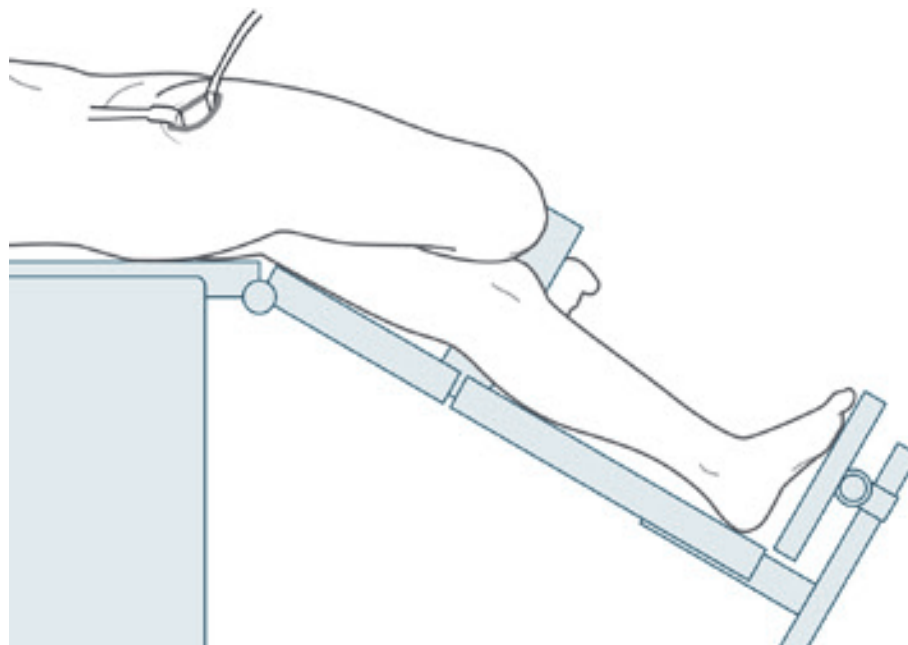


Fig. 29

In preparing the cup, starting with the femur can be very helpful. Use the table break to expose the proximal femur, by lowering the table.

Prepare the femur (femur-first technique)

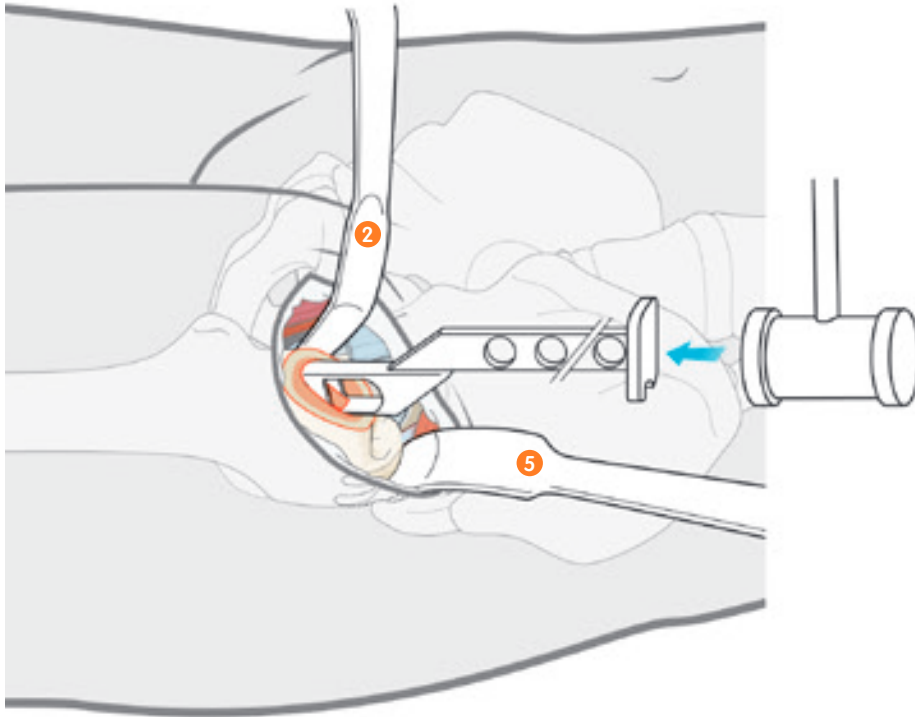


Fig. 30

Proceed with the preparation and broaching of the femoral shaft in accordance with the preferred surgical technique (The use of curved instruments may make this easier). In addition, use of a double offset broach handle is required.

Prepare the acetabulum

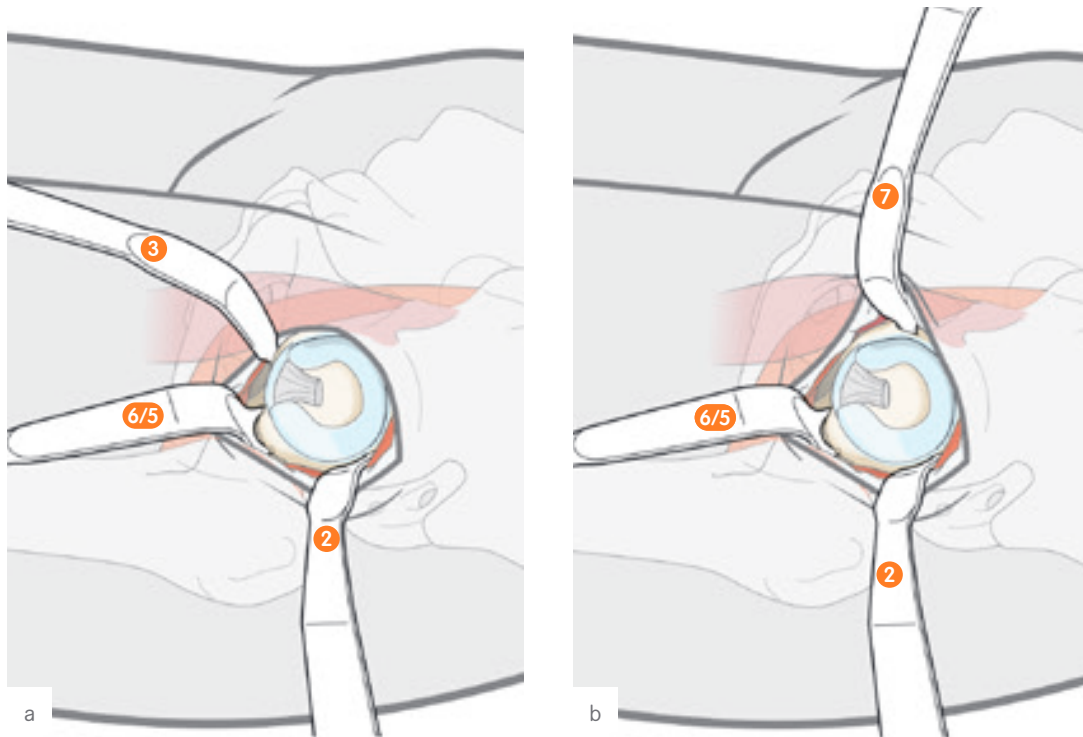


Fig. 31

Again, retractor placement is very important for ensuring sufficient exposure. The first retractor is placed in the acetabular fossa (S Bone lever double curved w. long soft-tissue protection ③), the second around the posterior acetabular wall (S Bone lever expanded double curved ②) and the third (S Hip lever ⑥, or sometimes S Trochanteric lever ⑤) goes around the posterior wall and inferior horn of the posterior wall of the acetabulum. These three retractors allow an initial assessment of the entire acetabulum.

After sufficient “soft tissue” debridement (cleaning) of the joint, replace the first retractor (③) with another (S Pelvis lever ⑦). This is placed on the anterosuperior acetabular rim within the capsule, so not to endanger the anterior neurovascular structures. Correct placement of this retractor is important.

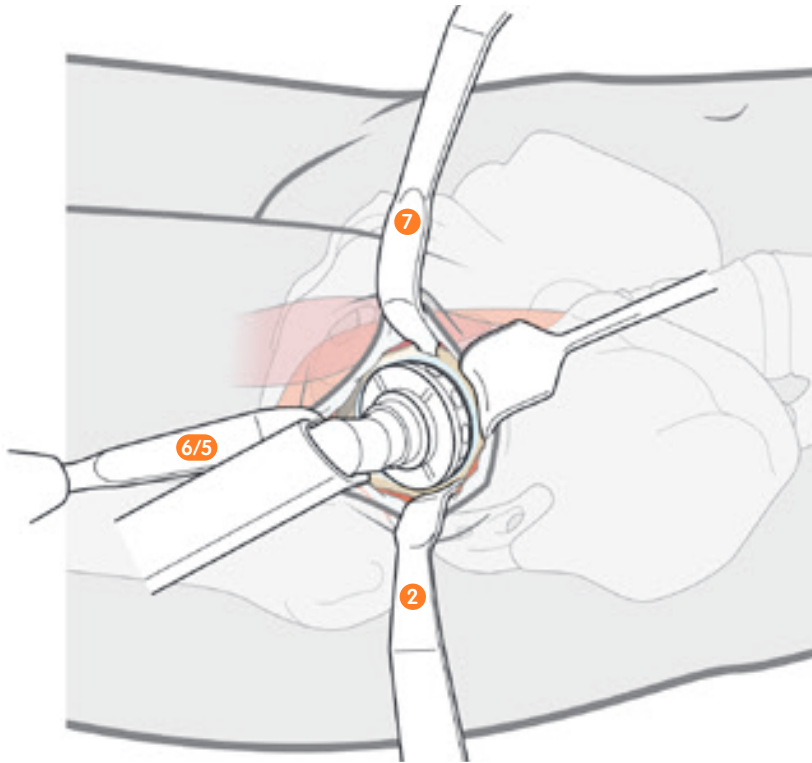


Fig. 32

Having replaced one retractor anteriorly with another inserted in the area of the anterior superior iliac spine, you can start the preparation and reaming of the acetabulum in accordance with your preferred surgical technique (The use of curved instruments makes this easier)

Insert the cup

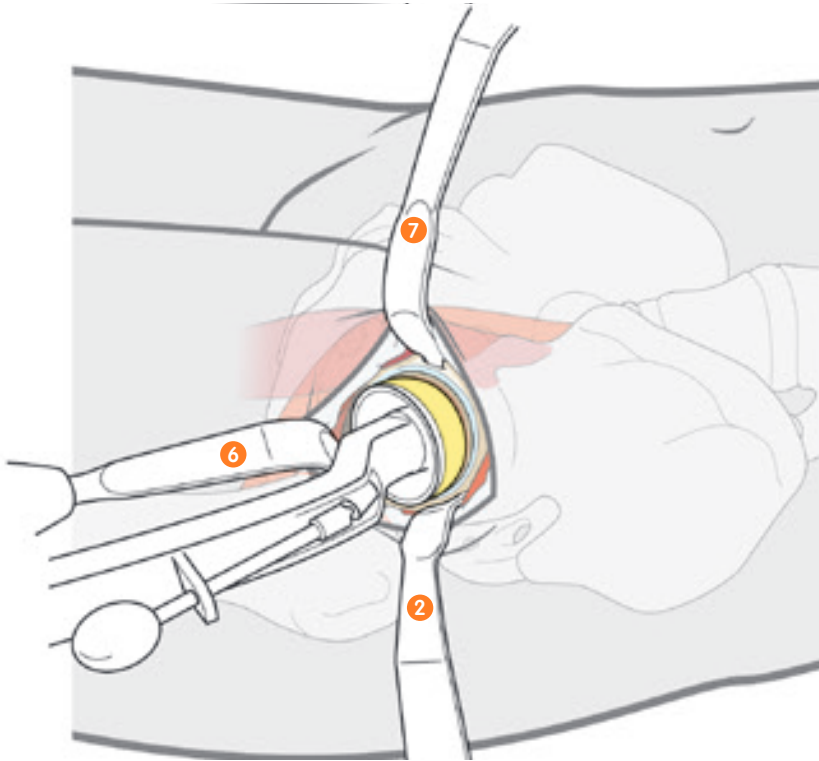


Fig. 33

Insert the cup in accordance with your preferred surgical technique, ensuring the necessary abduction and anteversion angles.

Assess cup orientation and stability

Using a trial head and trial neck, reduce and run through the range of motion movements to assess leg length and hip joint stability.

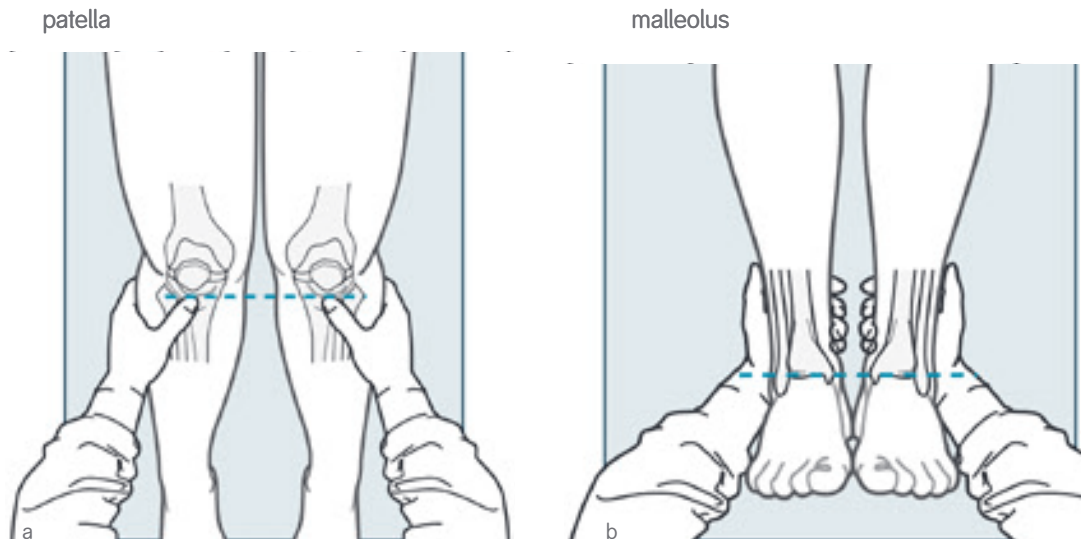


Fig. 34

Alternatively, check for leg length as shown here. Both legs are held in parallel. Palpate both patellae, as well as both medial malleoli and the heels, and check for correct leg length. Also ensure the the pelvis is not tilted by palpating the ASIS. This is particularly important for unilateral cases. In bilateral cases it is easier to adjust.

The femur-first technique allows you to assess cup orientation. If there is a problem with the orientation, it is possible to rectify at this stage. When satisfied, proceed with inserting the final components.

Insert the stem

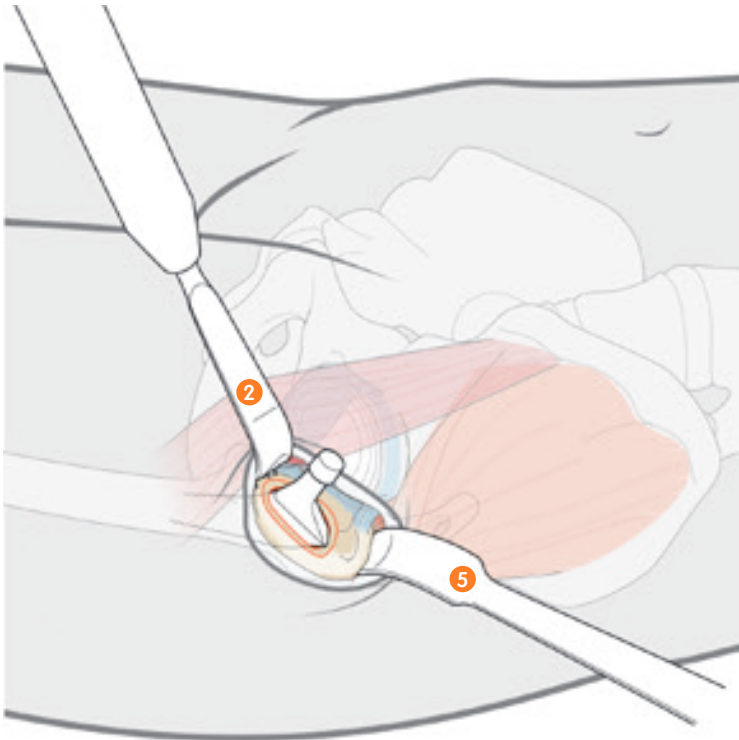


Fig. 35

Remove the broach and insert your implant.

Close the wound

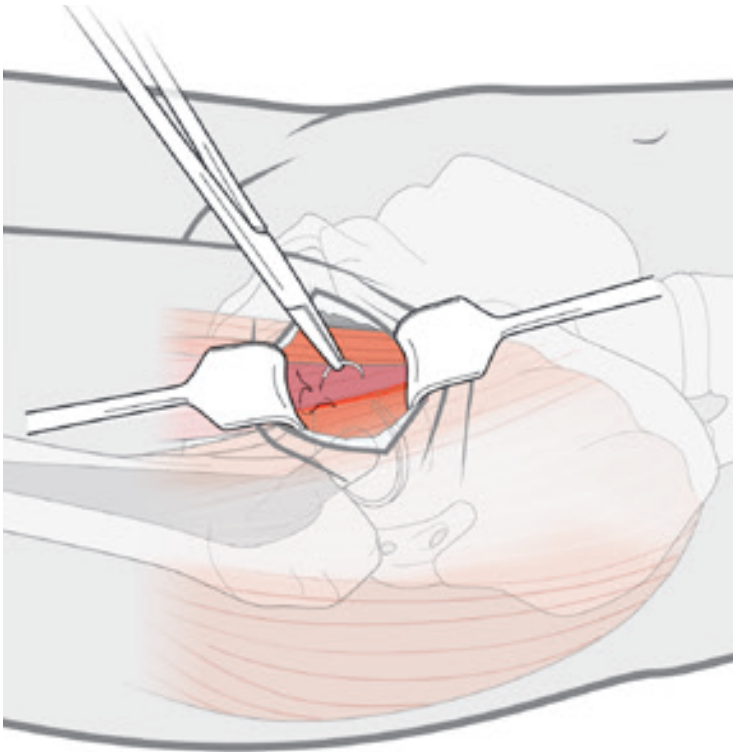


Fig. 36

Using two short blunt retractors, elevate the subcutaneous tissue and the skin; insert a running suture through the fascia layer of the tensor fasciae latae muscle. Next, insert interrupted stitches in the subcutaneous tissue and, finally, close the skin with an intracutaneous running suture using absorbable material.

To allow patients to take a shower soon after surgery, it is recommended to place an adhesive dressing over the wound.

Smith & Nephew Orthopaedics AG

Oberneuhofstrasse 10d

6340 Baar, Switzerland

T +41 41 766 22 55

Come and visit us at

www.smith-nephew.com/education